



Non-plug technique of bilayer patch device insertion for indirect inguinal hernia repair

Neutiskujuća tehnika ubacivanja dvolisne mrežice u reparaciji indirektno preponske kile

Miroslav Ilić*[†], Srdjan Putnik[†], Ivan Kuhajda*[†], Dejan Ivanov^{†‡}

Institute for Lung Diseases of Vojvodina, *Clinic for Thoracic Surgery, Sremska Kamenica, Serbia; University of Novi Sad, [†]Faculty of Medicine, Novi Sad, Serbia; Clinical Center of Vojvodina, [‡]Clinic for Abdominal, Endocrine and Transplant Surgery, Novi Sad, Serbia

Abstract

Background/Aim. Despite a huge success in decrease rate of recurrences of inguinal hernia in mesh and “plug in” techniques, a new problem appears such as chronic pain and other complications. The aim of this paper was to present the original modification of bilayer patch device (Prolene Hernia System®, Ethicon) insertion in “non-plugged” fashion and 11-year experience with this open technique for the indirect hernia repair in a male. **Methods.** This retrospective study included 96 male patients with 103 indirect unilateral and bilateral inguinal hernias, operated due to a primary or recurrent hernia in an 11-year interval (2004–2015). In all operation an extended Prolene Hernia System® (PHS) bilayer patch device was inserted medially of inferior epigastric vessels through a small incision in Hasselbach's triangle, thus avoiding plug component of device connector into the internal ring. All data were taken from the medical records, operative protocols, and telephone questionnaire. **Results.** Non-plugged technique of bilayer patch device insertion

was presented in details. Mean age of patients was 59 years. There were 3 (2.91%) patients with procedure-related complications, two patients with postoperative seroma and one with scrotal ecchymosis. There were 86 (89.6%) patients who answered on the questionnaire. During 11 years of following, recurrence of a hernia occurred in 1 patient, one had funiculocoele and only one had chronic pain during 6 months. Almost all patients (97.68%) were satisfied with the procedure and results of hernia surgery. **Conclusion.** Non-plugged insertion of bilayer patch device is a safe technique for solving the primary and recurrent indirect inguinal hernias. The low incidence of the recurrence and chronic pain many years after the operation justifies this technique even in hospitals not specialized for the hernioplasty.

Key words:

hernia, inguinal; surgical procedures, operative; surgical mesh; treatment outcome; pain, postoperative; surveys and questionnaires.

Apstrakt

Uvod /Cilj. Uprkos ogromnom smanjenju stope recidiva ingvinalne hernije primenom tehnike mrežice i „plug in“ tehnike, nastaju novi problemi, kao što je hroničan bol i druge komplikacije. Cilj rada bio je da se predstavi originalna modifikacija postavljanja dvolisne mrežice (*Prolene Hernia System*®, PHS, *Ethicon*) neutiskujućom tehnikom i 11-godišnje iskustvo sa tom otvorenom tehnikom u reparaciji indirektnih preponskih kila kod muškaraca. **Metode.** Retrospektivnom studijom obuhvaćeno je 96 bolesnika muškog pola sa 103 jednostrane odnosno obostrane preponske kile, operisane kao primarne ili recidivne, u 11-godišnjem intervalu (2004–2015). U svim operacijama korišćena je proširena *Prolene Hernia System*® (PHS) dvolisna

mrežica koja je postavljena medijalno od donjih epigastričnih sudova kroz inciziju u Haselbahovom trouglu, kako bi se izbeglo ubacivanje konektora u unutrašnji ingvinalni otvor. Svi podaci dobijeni su iz medicinske dokumentacije, operativnih protokola i telefonskog upitnika. **Rezultati.** Detaljno je prikazana neutiskujuća tehnika umetanja dvolisne mrežice (PHS) u hirurgiji indirektnih hernija. Prosečna starost bolesnika bila je 59 godina. Kod tri (2,91%) bolesnika registrovane su komplikacije povezane sa tehnikom, dva bolesnika imala su postoperativni serom, a jedan ekhimozu skrotuma. Na upitnik je odgovorilo 86 (89,6%) bolesnika. Tokom 11 godina praćenja recidiv kile razvio se kod jednog bolesnika, zabeležena je jedna funikulokela, a jedan bolesnik imao je hronični bol u periodu od šest meseci. Zadovoljstvo procedurom i

rezultatima operacije kile bilo je prisutno kod gotovo svih pacijenata (97,68%). **Zaključak.** Neutiskajuća tehnika postavljanja dvolisne prolenske mrežice u toku reparacije indirektno preponske kile sigurna je i bezbedna metoda kojom se mogu rešiti i primarne i recidivantne hernije. Niska stopa recidiva i hroničnog bola utvrđena dugotrajnim postoperativnim praćenjem opravdavaju široku primenu ove

tehniku i u centrima koji nisu usko specijalizovani za hernioplastike.

Ključne reči:

hernija, ingvinalna; hirurgija, operativne procedure; hirurška mrežica; lečenje, ishod; bol, postoperativni; ankete i upitnici.

Introduction

The evolution of an inguinal hernia's repair has gone through the phase of simple reposition, tension techniques based on Bassini's technique, and mesh techniques, open or laparoscopic [transabdominal preperitoneal (TAPP), totally extraperitoneal (TEP)]¹⁻⁴. "Plugged in" techniques are based on the insertion of synthetic, non absorbable, semi absorbable or absorbable materials into the internal inguinal hiatus, the weak point where the indirect inguinal hernia appears^{5,6}. Although there has been a huge success in decrease rate of recurrences in mesh and "plug in" techniques, a new problem appears such as chronic pain, erosive complications of intraperitoneal organs and rejection of artificial material⁷⁻¹¹. An ideal technique for an indirect hernia's repair is still not established.

Bilayer patch device (Ethicon, Prolene Hernia System® (PHS) Extended) made of polypropylene is three-dimensional mesh, with two patch layers (underlay and onlay) attached to the connector in order to keep both patches stable. It has been in use for the last 20 years. Although it was created as a two-layer patch (underlay and onlay) this device has a plug component connector. After the preparation of hernia's sac and reposition in preperitoneal space, the connector is placed through the internal inguinal hiatus and underlay patch is placed in preperitoneal space. In original technique, the spermatic cord is located close to the connector and it can be compressed above through the internal inguinal hiatus, so the space for the spermatic cord is created laterally through the narrowest side of onlay mesh. Onlay mesh has to cover the space between internal oblique's muscle and inguinal ligament^{6,12}.

"Plugged in" component has been accused of the late complications in an indirect hernia's repair with this technique in some papers^{8,9}.

The aim of this paper was to explain in details the original modification of bilayer patch device insertion in non-plugged fashion and 11-year clinical experience with this technique, as well as early, midterm and late results for the male indirect hernia repair in the tertiary surgical institution not specialized for hernia surgery.

Methods

This retrospective study included 96 male patients operated due to indirect primary or recurrent inguinal hernias between November 2004 and December 2014. Among them, 7 patients had bilateral inguinal hernias, in total numbers of 103 indirect hernias. All the operations were done by one

general surgeon in the tertiary surgical institution specialized for thoracic and esophageal surgery. All the patients received preoperatively one dose of antibiotics. All hernioplasty procedures were done under general anesthesia. In all operations, an extended PHS mesh was used with non-plugged insertion technique with bilayer patch device (PHS®, Ethicon). All patients were discharged from the hospital on first postoperative day.

All data were taken from the medical records and operative protocols. For late complications and quality of life, a subject-related questionnaire was made and fulfilled during the telephone call. The focus was intolerance of patch, chronic pain, recurrent hernias or other complications on intraperitoneal organs.

Operative technique

With the skin incision of about 4 cm above the inguinal canal, the fascia of abdominal external oblique muscle was opened from the spermatic cord to internal inguinal ring. After the identification of spermatic cord structures and nerves of inguinal region, the hernia sac was dissected, pulling back into preperitoneal space without resection. Original modification of the technique did not include a preperitoneal space for underlay patch through internal ring, but medially from the inferior epigastric blood vessels in Hesselbach's triangle, by making a small incision of about 15 mm on transversal fascia, parallelly with the inferior epigastric blood vessels (Figure 1a), where the PHS connector were placed.

In preperitoneal space (space of Borgos), a place for the underlay patch was made with moist gauze covering the internal hernia hiatus from the back side (Figure 1b). Lateral and lower end of the underlay patch was set above the femoral blood vessels. In this fashion, the connector of the bilayer patch device PHS was positioned on the spot where a direct hernia could hypothetically appear. The underlay patch covered internal hernia hiatus and all the other weak points of preperitoneal space of inguinofemoral region.

The small Y incision was made on the longest diameter of the onlay patch on about 15 mm from the connector and the spermatic cord was placed through it (Figure 1c). Above the spermatic cord, the transected part of the onlay mesh was approximated with Prolene 2.0 stitches except for the Y incision.

The onlay mesh has to cover the pubic tubercle for 2 cm and to be sutured with Prolene 2.0 for the inguinal ligament, and for the internal oblique muscle, but avoiding iliohypogastric nerve. The upper part of the onlay mesh was pushed beneath the external oblique muscle aponeurosis and

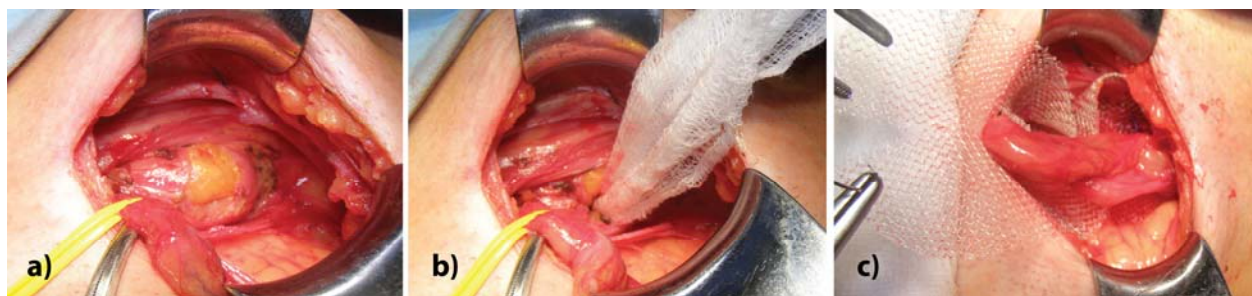

Fig. 1 – Original non plug technique of bilayer patch device insertion for repairing of indirect inguinal hernia: a) medial approach from the inferior epigastric blood vessels in Hesselbach's triangle through small incision of about 15 mm; b) application of underlay patch with moist gauze in preperitoneal space (space of Borgos); c) the small Y incision on the longest diameter on the onlay patch on about 15 mm from the connector and the spermatic cord placed through it.

sutured with usually six Prolene 2.0 stitches. The operation was finished with the skin sutured.

Results

A total of 96 male patients with 103 indirect inguinal hernias were operated by non-plugged insertion of bilayer patch device technique. The mean age of patients was 59.26 (range, 27–91 years). In 49 (51%) patients the hernia was on the right side, in 40 (41.7%) patients on the left side, while 7 (7.3%) had bilateral hernias. The primary indirect inguinal hernia was seen in 96 (93.2%) and the recurrent indirect inguinal hernia in 7 (6.8%) patients.

In patients with bilateral indirect hernias we did the same procedure on both sides using the same original modification. There were 7 (6.8%) patients with recurrent indirect hernias, where operation lasted for a longer time and where the identification of inguinal anatomy was more difficult, but the same procedure of mesh insertion was done.

Figure 2 shows data about a number of operated patients *per* year. Our institution is a low-volume center for hernioplasty with 3 to 17 operations *per* year.

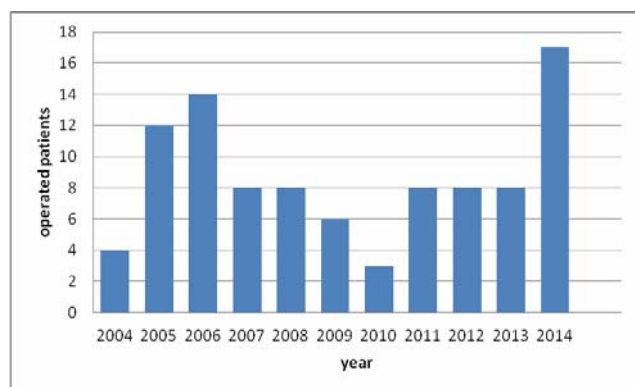


Fig. 2 – Number of patients operated because of the hernia *per* year.

Among 96 operated patients, 86 (89.6%) patients answered all questions and 10 (10.4%) patients died in the meantime, so the information was given by their families.

After the modification of non-plugged PHS mesh insertion, there were 3 relating problems regarding the procedure, of which two (1.94%) lesions of epigastric vessels and one

(0.97%) accidental damage of hernias bag. There were 3 patients with early postoperative complications: two (1.94%) patients with seromas and one (0.97%) patient with scrotal wall ecchymosis. Late postoperative complications appeared in 3 patients, chronic pain in one patient, funiculocoele in other patient and one recurrence hernia (0.97%).

The patient with recurrence of a hernia had complicated pelvic fracture due to the traffic accident a year before the primary operation. He appeared 4 years after the PHS operation, with a contralateral new inguinal hernia. That new hernia was operated with the same PHS modification technique, while the recurrent hernia was solved with additional onlay patch, without taking out the previously inserted PHS mesh.

The patient with the funiculocoele had the other operation in the other hospital, and the PHS mesh was taken out. However, the previous operator and the other hernia surgeon expert claimed that it was not the relapse.

Among all 86 operated patients, 84 (97.68%) were found to be satisfied with the result of the operation, 1 (1.16%) patient was unsatisfied with the operation.

The unsatisfied patient in this study reported his disappointment with the laparoscopic appendectomy which was performed in the same act.

The follow-up period after the surgery in surveyed patients is shown in Figure 3.

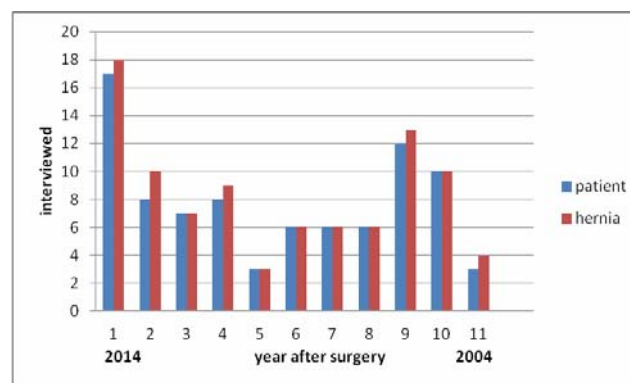


Fig. 3 – The follow-up period after surgery.

The follow-up period of operated patients ranged from 1 to 11 years, with the mean interval of 5 years and 6 months. Up to 4 years of follow-up there were a total of 40 (46.5%) patients and 44 (47.8%) indirect inguinal hernias.

Over 4 years of follow-up, there were 46 (53. 5%) patients and 48 (52. 2%) indirect hernias.

Discussion

In the original description about the usage of PHS mesh for the indirect hernias, the connector is set as the plug in the internal inguinal ring, and the opening for the spermatic cord is set centrally or laterally, but in both cases, the spermatic cord is in the contact with the connector¹². In our modification, we decided to place the connector medially of inferior epigastric blood vessels, avoiding the pressure on the spermatic cord providing underlay mesh much easier to place into preperitoneal space. In this position, the connector is not in the contact with the intraperitoneal organs, but only underlay mesh. The onlay mesh is set identically as in the Lichtenstein technique³. In this fashion, the onlay mesh sutured with the six Prolene 2.0 stitches prevents the migration of the underlay mesh. With this position of the connector and the both meshes, a double protection of internal inguinal hiatus is achieved and the spermatic cord is not compressed by the connector in the internal inguinal ring.

Potentially weak spot on transversal fascia is protected with the connector and the appearance of the recurrent hernias is prevented.

Positioning of PHS meshes in this fashion is very important in cases of large indirect inguinal hernias or with accidental lesions of hernia sac (one patient in this study), due to medial position of the connector, so there is no risk of hernia sac re-damaging while creating the space for the underlay through the internal inguinal ring.

Using this method, we did not have a complication like the migration of the mesh or damaging of intraperitoneal organs, like it is described in some recent papers about classical PHS technique^{9, 10}. We had only one recurrent hernia, four years after the operation, with the expansion of the internal inguinal ring over the underlay and onlay patches. This problem was solved with the additional onlay patch with no need of removing the PHS mesh which was in the primary position. Funiculocele in one patient was solved by taking out the PHS mesh in the other hospital, without any information how the hernia was resolved. Our results with this modification show low rate of the recurrences and late complications. Only one patient had chronic pain, reported also by other authors¹³ which lasted up to 6 months.

It is well known that the beginning and the development of the indirect inguinal hernias are connected with the pain in the inguinal region. The pain is caused by nerves of the ilioinguinal region, especially with the genital branch of the genitofemoral nerve, ilioinguinal nerve, sympathetic nerves (testicular plexus) which are included in spermatic cord¹⁴. The pain during the developing of indirect inguinal hernia is not proportional to the size of the internal inguinal ring defect. The classification of indirect inguinal ring size is more descriptive than the need for the

certain type of hernioplasty. Even in recurrent indirect inguinal hernias the pain is very common⁷.

We believe that the low incidence of the chronic pain in this modification technique is the result of less manipulation in the region of internal inguinal ring¹⁵, as well as no pressure on the spermatic cord by the connector, with making the Y incision on the onlay patch¹⁶. The low incidence of the pain is established with the usage of Prolene stitches for onlay mesh fixation and obligatory identification and avoidance of the nerves with the stitches.

Although the telephone survey was very considered of the postoperative pain, as well as for the general satisfaction with the operation, the majority of the patients declared they would have the same operative procedure if necessary¹⁷. One unsatisfied patient reported his disappointment with the laparoscopic appendectomy which was performed in the same act and not with the inguinal hernia repaired. With obtained data on the satisfaction and the low incidence of postoperative pain, we conclude that this modified technique is very acceptable for all the patients who underwent the operation.

The majority of the patients in this study were elderly patients, unlike some other studies¹⁸, with some other comorbidities, so the antibiotic prophylaxis and general anesthesia were justified. The antibiotic prophylaxis was the reason why we did not have wound infections¹⁹.

The absence of local or regional anesthesia in this study did not have any influence on postoperative pain. This technique could be done in local anesthesia, regarding new trends in herniology with shorter hospital stay, especially in hernia clinics⁷.

Non-plugged PHS technique is safer and much easier to learn than some other open techniques, and especially laparoscopic techniques, which are more demanded with much longer learning curves^{7, 20}.

In this study, we have two lesions of inferior epigastric blood vessels, during the transversal fascia transaction, which were solved by ligations.

With this technique, we solved primary, bilateral and recurrent hernias and showed that this technique is applicable for all indirect inguinal hernias results, despite of some other studies in which PHS for recurrent hernias were not used^{18, 21}.

Conclusion

Original modification of Prolene Hernia System[®] hernioplasty in non-plugged fashion is a safe modification of the original technique for solving the primary and recurrent indirect inguinal hernias, regarding our 11-year experience in tertiary surgical centre. Low incidence of the recurrence and chronic pain many years after the operation justifies this procedure even in hospitals not specialized for the hernioplasty. The major advantage of this modification is the absence of the connector in the internal inguinal ring and its pressure on the spermatic cord and nerves, as well as its position which does not interfere with intraperitoneal organs.

R E F E R E N C E S

1. Bassini E. Nuovo metodo operativo per la cura dell'ernia inguinale. Padova: Prosperini; 1889.
2. Rutkow IM, Robbins AW. "Tension-free" inguinal herniorrhaphy: a preliminary report on the "mesh plug" technique. *Surgery* 1993; 114(1): 3–8.
3. Lichtenstein IL, Shulman AG, Amid PK, Montllor MM. The tension-free hernioplasty. *Am J Surg* 1989; 157(2): 188–93.
4. Schultz L, Graber J, Pietrafita J, Hickok D. Laser laparoscopic herniorrhaphy: a clinical trial preliminary results. *J Laparoendosc Surg* 1990; 1(1): 41–5.
5. Robbins AW, Rutkow IM. The mesh-plug hernioplasty. *Surg Clin North Am* 1993; 73(3): 501–12.
6. Gilbert AI, Young J, Graham MF, Divilio LT, Patel B. Combined anterior and posterior inguinal hernia repair: Intermediate recurrence rates with three groups of surgeons. *Hernia* 2004; 8(3): 203–7.
7. Simons MP, Aufenacker T, Bay-Nielsen M, Bouillot JL, Campanelli G, Conze J, et al. European Hernia Society guidelines on the treatment of inguinal hernia in adult patients. *Hernia* 2009; 13(4): 343–403.
8. Chen MJ, Tian YF. Intraperitoneal migration of a mesh plug with a small intestinal perforation: report of a case. *Surg Today* 2010; 40(6): 566–8.
9. Lo DJ, Bilimoria KY, Pugh CM. Bowel complications after prolene hernia system (PHS) repair: a case report and review of the literature. *Hernia* 2008; 12(4): 437–40.
10. Zuvella M, Krivokapic Z, Galun D, Markovic V. Rare late mesh complications following inguinal prolene hernia system hernioplasty: report of three cases. *Surg Today* 2012; 42(12): 1253–8.
11. Yamamoto S, Kubota T, Abe T. A rare case of mechanical bowel obstruction caused by mesh plug migration. *Hernia* 2015; 19(6): 983–5.
12. Gilbert AI, Graham MF, Voigt WJ. A bilayer patch device for inguinal hernia repair. *Hernia* 1999; 3(3): 161–6.
13. Campanelli G, Bertocchi V, Cavalli M, Bombini G, Biondi A, Tentorio T, et al. Surgical treatment of chronic pain after inguinal hernia repair. *Hernia* 2013; 17(3): 347–53.
14. Skandalakis JE, Colborn GL, Pemberton LB, Skandalakis LJ, Gray SW. The surgical anatomy of the inguinal area — Part 2. *Contemp Surg* 1991; 38(2): 28–38.
15. Stark E, Oestreich K, Wendl K, Ramstadt B, Hagmüller E. Nerve irritation after laparoscopic hernia repair. *Surg Endosc* 1999; 13(9): 878–81.
16. Hsu W, Chen CS, Lee HC, Liang HH, Kuo LJ, Wei PL, Tam KW. Preservation versus division of ilioinguinal nerve on open mesh repair of inguinal hernia: a meta-analysis of randomized controlled trials. *World J Surg* 2012; 36(10): 2311–9.
17. Alfieri S, Amid PK, Campanelli G, Izard G, Kehlet H, Wijsmuller AR, et al. International guidelines for prevention and management of post-operative chronic pain following inguinal hernia surgery. *Hernia* 2011; 15(3): 239–49.
18. Yener O, Aksoy F, Güzel P, Bölük S, Dağ E, Atak T. Long-term quality of life after hernioplasty using a Prolene hernia system in adult inguinal hernia. *Hernia* 2012; 16(1): 29–32.
19. Mazaki T, Mado K, Masuda H, Shiono M. Antibiotic prophylaxis for the prevention of surgical site infection after tension-free hernia repair: a Bayesian and frequentist meta-analysis. *J Am Coll Surg* 2013; 217(5): 788–801.
20. Lovisetto F, Zonta S, Rota E, Bottero L, Faillace G, Turra G, et al. Laparoscopic transabdominal preperitoneal (TAPP) hernia repair: surgical phases and complications. *Surg Endosc* 2007; 21(4): 646–52.
21. Mottin CC, Ramos RJ, Ramos MJ. Using the Prolene Hernia System (PHS) for inguinal hernia repair. *Rev Col Bras Cir* 2011; 38(1): 24–7.

Received on September 1, 2015.

Revised on November 10, 2015.

Accepted on January 11, 2016.

Online First September, 2016.